

## RESEARCH ARTICLE

Elenka Georgieva<sup>1</sup>  
Victoria Sarafian<sup>2</sup>

## Expression of blood group antigens A and B in pancreas of vertebrates

### Authors' addresses:

<sup>1</sup> Department of Developmental Biology, Faculty of Biology, Plovdiv University, Plovdiv, Bulgaria.

<sup>2</sup> Department of Medical Biology, Medical University of Plovdiv, Plovdiv, Bulgaria.

### Correspondence:

Elenka Georgieva  
Faculty of Biology  
Plovdiv University  
24, Tsar Assen Str.  
4000 Plovdiv, Bulgaria  
Tel.: +359 32 261535  
e-mail: elenatomova@uni-plovdiv.bg

### Article info:

Received: 06 April 2012

Accepted: 30 April 2012

### ABSTRACT

The biological role of blood group antigens (BGA) A and B in tissues of different vertebrates is still controversial. There are few investigations on vertebrate pancreas and no obvious explanation of their tissue expression. The aim of the present study is to follow and compare the pancreatic expression of BGA A and B in representatives of five vertebrate classes. The biotin-streptavidin-proxidase labeling system was used for immunohistochemical detection of BGA by monoclonal antibodies to human A and B antigens. The present study reveals specific immunoreactivity in acinar and epithelial cells of pancreatic efferent ducts in species free-living vertebrates. The immunoperoxidase staining shows antigenic heterogeneity in the cellular localization. The number of positive cells and the intensity of expression vary in different species. Endothelial cells are positive only in the pancreas of *Emys orbicularis*. The lack of BGA A and B in some species suggests that the expression of these antigens is dependent not only on the evolutionary level of the species, but mainly on some genetic control mechanisms. The production of BGA A and B and the variability in their cellular localization probably reflect the stage of cell differentiation and the mechanisms of pancreatic secretor function. The presence of histo BGA in endodermal acinar pancreatic cells confirms the assumption for the high antigenic stability and conservatism of these molecules in vertebrate histogenesis and evolution.

**Key words:** A and B blood group antigens, immunohistochemistry, pancreas, vertebrates

## Introduction

Human ABH blood group antigens (BGA) are genetically determined glycosphingolipids and glycoproteins. Although first discovered on human red blood cells, they were later found in different other cell types and body fluids. Their localization in tissues of humans and other mammals gives grounds to assume that they are histo-BGA rather than red blood cell associated. Their genetic and biochemical properties are well studied in humans. The ABO genes are already cloned (Yamamoto, 1995; Morgan & Watkins, 2000; Oriol et al., 2000) and identified in primates (Kominato et al., 1992). The participation of blood group antigens in cellular interactions, cell differentiation and tumor metastasis is still disputable (Sarafian et al., 1994; Cartron, 1996, Nishimura et al., 2001). Their presence in animal tissues

poses many questions regarding the immunobiological functions of these molecules in vertebrate evolution.

The present study is aimed at investigating and comparing the pancreatic expression of blood group antigens A and B free-living in representatives of five vertebrate classes.

## Materials and Methods

Four individuals from each of the twelve different animal species belonging to the following vertebrate classes were examined:

- Class *Osteichthyes*, suborder *Cypriniformes*, family *Cyprinidae*, genus *Cyprinus*, species - *Cyprinus carpio* (Linn, 1758); species - *Carassius auratus* (Bloch, 1783);
- Class *Amphibia*, order *Urodela*, family *Salamandridae*, genus *Triturus*, species - *Triturus cristatus*,

## RESEARCH ARTICLE

(Laurenti, 1768); order *Anura*, family *Bufo*, genus *Bufo*, species - *Bufo viridis*, (Laurenti, 1768); genus *Rana*, family *Ranidae*, species - *Rana ridibunda* (Pall, 1771);

- Class *Reptilia*, order *Squamata*, suborder *Lacertilia*, family *Lacertidae*, genus *Lacerta*, species - *Lacerta muralis* (Laurenti, 1768); species - *Lacerta viridis* (Laurenti, 1768); order *Chelonia*, family *Emyidae*, genus *Emys*, species - *Emys orbicularis* (Linn, 1758); suborder *Ophidia*, family *Colubridae*, genus *Natrix*, species - *Natrix natrix* (Linn, 1758).

- Class *Aves*, order *Passeriformes*, family *Fringilidae*, genus *Passer*, species - *Passer montanus* (Linn, 1758); family *Ploceidae*, genus *Carduelis*, species - *Carduelis carduelis* (Linn, 1758).

- Class *Mammalia*, order *Rodentia*, family *Muridae*, genus *Apodemus*, species - *Apodemus flavicollis* (Melchior, 1834).

Paraffin sections from the species studied were investigated by the biotin-streptavidin-proxidase labeling system (DAKO LSAB kit). As primary antibodies for the immunohistochemical detection of blood group antigens monoclonal antibodies to human A and B antigens were used. A 2% solution of AEC was used as a substrate chromogen. The nuclei were counterstained with Mayer hematoxyllin. As a positive reaction was considered the red-brownish granular staining in cell cytoplasm or plasma membrane. It was read according to a semiquantitative scale: (++) - 80-100% positive cells; (+) - 40-50% positive cells; (+/-) - 10-15% - positive cells; (-) - no positive cells. For each tissue section a negative control was performed.

In order to exclude nonspecific binding of monoclonal antibodies to animal tissues inhibition tests were carried out - the antibodies were preabsorbed with human red blood cells, immunodominant sugars (N-acetyl-D-galactosamine и D-galactose) and animal red blood cells. The presence of antigenic heterogeneity was detected as a varying intensity of the immunoperoxidase reaction, as well as a various cellular localization of blood group antigens.

## Results

The acinar and the epithelial cells of pancreatic efferent ducts were positive for blood group antigens A and B. The reaction was characterized by antigenic heterogeneity of cellular localization. The number of positive cells, as well the intensity of reactivity varied in different species. The

endothelial cells in all vertebrates were negative for blood group antigens except in the pancreas of *Emys orbicularis*. The red blood cells, the connective tissue and muscle cells in all animals studied expressed no blood group antigens.

### *Class Osteichthyes*

The hepatopancreas of two representatives of the *Cyprinidae* family was examined - *Cyprinus carpio* and *Carassius auratus*. BGA A was found in 40-50% of epithelial cells of the exocrine pancreas of *Cyprinus carpio* (Figure 1a). The reactivity was mainly cytoplasmic with high intensity. The pancreas of *Carassius auratus* showed no A and B blood group antigens.

### *Class Amphibia*

Only BGA B was detected in pancreatic acini of *Triturus cristatus* (Figure 1b). The reaction was localized chiefly in the apical part of epithelial cells. The intensity and number of immunopositive cells varies in different individuals.

In both frog species blood group antigens were found only in the acini of exocrine pancreas. Only B antigen was detected in the acini of exocrine pancreas of *Rana ridibunda*, while in *Bufo viridis* (Figure 1c) both antigens were discovered. The cytoplasmic reactivity was mostly apical or perinuclear. The reactivity for BGA B was in the form of large cytoplasmic granules, while for A antigen there were small scattered granules in the cytoplasm.

### *Class Reptilia*

In the pancreas of *Lacerta muralis* and *Lacerta viridis* no blood group antigens were detected.

The pancreas of *Natrix natrix* was also negative. In *Emys orbicularis* a cytoplasmic reactivity with high intensity for both antigens was identified in acinar cells (Figure 1d). Antigenic heterogeneity regarding the number of positive cells and their localization was observed - the reactivity was frequently apical and perinuclear rather in the whole cytoplasm. BGA were uncovered in epithelial cells lining the inner surface of efferent secretor ducts (Figure 1e). The endothelium of all blood vessels was positive for BGA A. Red blood cells, the interacinar area and the connective tissue elements in it were always immunonegative.

### *Class Aves*

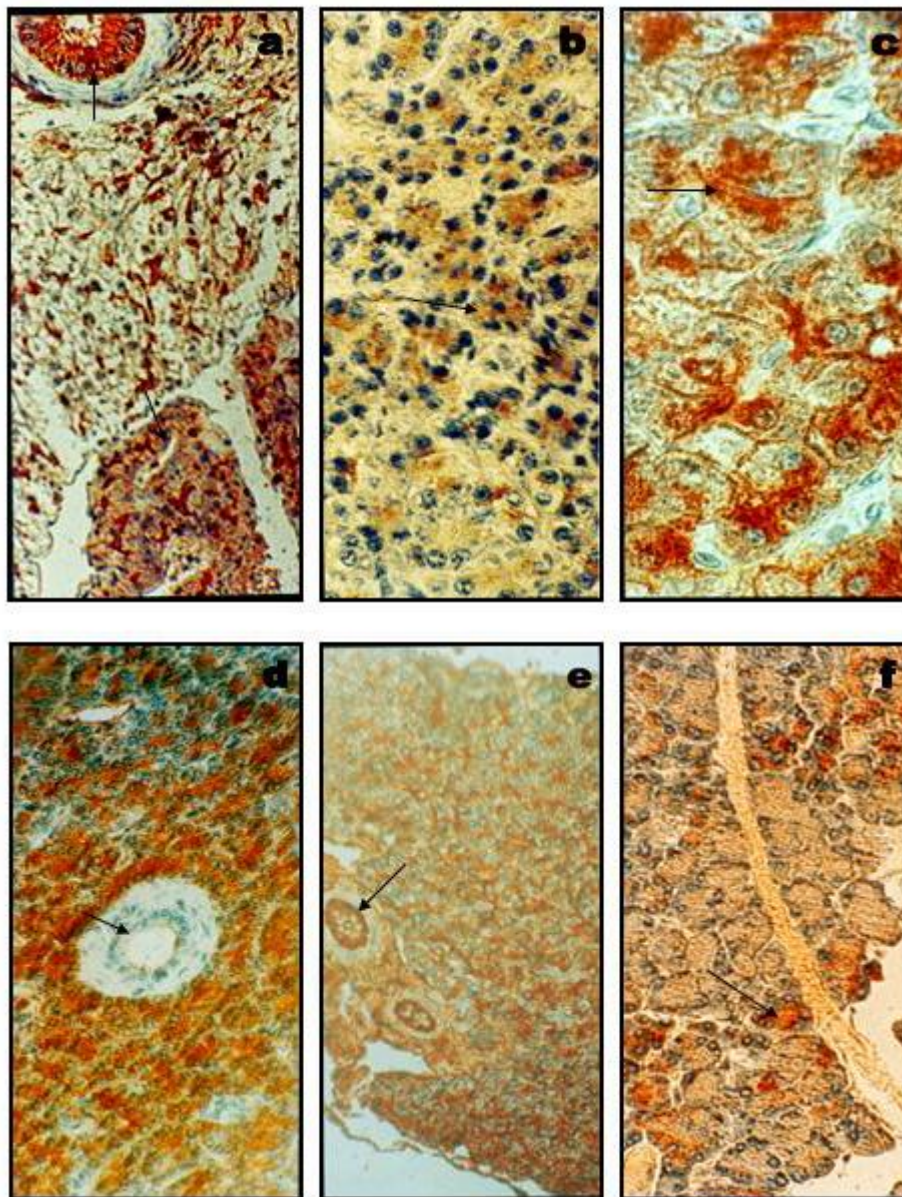
A and B blood group antigens demonstrated various

## RESEARCH ARTICLE

expression patterns in the representatives of this class. Antigen B had a higher level of expression in the acinar epithelial cells of *Passer montanus*. The pancreas of *Carduelis carduelis* revealed no blood group antigens.

**Class Mammalia**

In *Apodemus flavicollis* both blood group antigens were found in acinar cells only. Antigenic heterogeneity concerning the number of positive cells with cytoplasmic reactivity was noticed (Figure 1f).



**Figure 1.** Expression of blood group antigens A and B in exocrine pancreas of vertebrates. Biotin-streptavidin-peroxidase reaction.

**a)** BGA A in hepatopancreas of *C. carpio*, granular reaction in acinar cells, x400. **b)** BGA B in pancreatic acinar cells of *T. cristatus*, x400. **c)** BGA B in *B. viridis*, cytoplasmic and membrane bound reaction, x600. **d)** BGA A in *E. orbicularis*, cytoplasmic reactivity in acini and in the endothelium of blood vessels, membrane staining of cells in efferent ducts, x400. **e)** BGA A in *E. orbicularis*, cytoplasmic staining in efferent ducts, x200. **f)** BGA B in pancreatic acini of *A. flavicollis*, x400.

## RESEARCH ARTICLE

## Discussion

The present study is the first attempt to perform a systematic immunohistochemical investigation of pancreatic expression of blood group antigens A and B in representatives of free-living vertebrates from different animal classes. Blood group antigens A and B are found in the secretory epithelial cells of pancreatic exocrine acini in *C. carpio*, *T. cristatus*, *R. ridibunda*, *B. viridis*, *E. orbicularis*, *P. montanus* and *A. flavicollis*. The antigenic heterogeneity in cellular localization and the luminal expression in pancreatic acini is probably a result from the production and secretion of blood group antigens from the exocrine epithelial cells. A similar finding is recorded by different techniques in other species. BGA H is documented by immunofluorescence in the pancreas of newborn rats (Oriol et al., 1992). In American apes, marsupilians and other mammals expression of  $\alpha$ Gal in pancreatic ducts and acini is detected. As it lacked in Langerhans islets, the authors suggest that cell maturation and differentiation should possibly matter (Oriol et al., 1999). Secretory cells in rat and cat salivary glands also express ABH antigens. Human acinar cells express ABH antigens under the control of *Se*-genes, while pancreatic ducts express Lea and Leb antigens controlled by *Se*- and *Le*-genes (Ito et al., 1990).

We assume that the absence of sugar residues with A- and B-specificity is a possible cause for the negative immunoperoxidase reaction in exocrine pancreatic acini in *C. auratus*, *L. viridis*, *L. muralis*, *N. natrix* and *C. carduelis*. The lack of histo BGA in these species might be related to other causes leading to a block in some of the biosynthetic stages. Ontogenetic studies of Takiyama et al. (1990) also reveal immunonegativity in pancreas of fetal, newborn and adult hamsters.

Our results like those of other research teams demonstrate diversity in the expression of the carbohydrate A and B blood group antigens in the pancreas of different vertebrates. There is no evidence for other investigations on the species examined in the present study, at least in evolutionary aspect. A specific expression of blood group antigens in acinar epithelial cells in different species was detected showing a distinct antigenic heterogeneity in cell localization. The stage of cell differentiation is assumed as being an important factor for this expression pattern but not the evolutionary level of the species. Other influencing factors and mechanisms could not be excluded either. It is quite possible that the production of blood group determinants and the variability in cell

localization are dependent on the state of exocrine epithelial cells and their secretor function. This may explain the antigenic positivity in epithelial cells of pancreatic efferent ducts in *E. orbicularis* and in *C. carpio*.

Our findings distinctly show that permanently positive for A and B blood group antigens are pancreatic endodermal acinar epithelial cells. Their presence from *Pisces* to *Mammals* (as well as in humans according to literature data) supposes a high stability and evolutionary stability of these carbohydrate structures. The present study together with our previous investigations (Tomova et al., 2001; Sarafian et al., 2004; Sarafian & Tomova, 2004) give us grounds to believe that epithelial cells with endodermal origin are the cell type which most permanently expresses histo BGA in vertebrates.

In all species studied endothelial cells were positive only in *E. orbicularis*. According to phylogenetic studies ABH antigens appear on red blood cells very late in the evolutionary process – in primates and humans (Oriol, 1987; Oriol et al., 1986, 1992; Blancher et al., 1999; Kermarres et al., 1999). Endothelial cells express blood group antigens only in higher mammals like chimpanzees, gorillas, orangutans and baboons (Oriol et al., 1993; Oriol & Cooper, 1997; Oriol et al., 1999). Our study reveals A and B antigens only in endothelial cells of the representative of reptiles - *Emys orbicularis*. This finding may suggest that A and B blood group antigens appeared quite early in the evolution of vertebrates – in mesodermal epithelial derivatives like endodermal cells. It could not be excluded that a possible participation of blood group determinants in cell interactions, contact inhibition and adhesion could determine this pattern of expression.

## References

- Blancher A, Roubinet F, Reld M., Sosha WW. 1999. Anti-human red cell monoclonal antibodies produced by macaque-mouse heterohybridomas: their reactivity with human and nonhuman primate erythrocytes. *J. Med. Primatol.*, 28(3): 118-128.
- Cartron JP. 1996. A molecular approach to the structure, polymorphism and function of blood groups. *Transfus. Clin. Biol.*, 3(3): 181-210.
- Ito N, Nishi K, Nakajima M, Okanura Y, Hirota T. 1990. Histochemical localization and analysis of blood group-related antigens in human pancreas using immunostaining with monoclonal antibodies and exoglycosidase digestion. *J. Histochem. Cytochem.*, 38(9): 1331-1340.
- Kermarres N, Roubinet F, Apoil P, Blancher A. 1999. Comparison of allele O sequences of the human and non-human primate

## RESEARCH ARTICLE

- ABO system. *Immunogenetics*, 49(6): 517-526.
- Kominato Y, McNeill PD, Yamamoto M, Russell M, Hakomori S, Yamamoto F. 1992. Animal histo-blood group ABO genes. *Biochem. Biophys. Res. Commun.*, 189(1): 154-164.
- Morgan WT, Watkins WM. 2000. Unraveling the biochemical basis of blood group ABO and Lewis antigenic specificity. *Glycoconj. J.*, 17(7-9): 501-530.
- Nishimura A, Yamamoto Y, Nishi K. 2001. Expression of ABH and ABH-related antigen in secretory cells of indoor pets. Species analysis should be necessary prior to ABO blood grouping in stain analysis. Anil Aggrawal's Internet J. Forens Med. *Toxicology*, 2(2): (July-Dec 2001).
- Oriol R, Candelier J, Mollicone R. 2000. Molecular genetics of H. *Vox Sang.*, 78(Suppl. 2): 105-108.
- Oriol R, Candelier J, Taniquishi S, Balanzino L, Peters L, Niekrasz M, Hammer C, Cooper DK. 1999. Major carbohydrate epitopes in tissues of domestic and African wild animals of potential interest for xenotransplantation research. *Xenotransplantation*, 6(2): 79-89.
- Oriol R, Cooper DKC. 1997. Four major carbohydrate xenotransplantation antigens. – In: Cooper DKC, Kemp E, Platt JL, White DJ. (Eds), *The transplantation of organs and tissues between species*, Xenotransplantation, Springer-Verlag, p. 24-32.
- Oriol R, Le Pendu J, Mollicone R. 1986. Genetics of ABO, H, Lewis, X and related antigens. *Vox Sang.*, 51(3): 161-171.
- Oriol R, Mollicone R, Coullin P, Dalix AM, Candelier JJ. 1992. Genetic regulation of the expression of ABH Lewis antigens in tissues. *APMIS Suppl.*, 27: 28-38.
- Oriol R, Ye Y, Koren E, Cooper DK. 1993. Carbohydrate antigens of pig tissue reacting with human antibodies as potential targets for hyperacute vascular rejection in pig-to-man organ xenotransplantation. *Transplantation*, 56(6): 1433-1442.
- Oriol R. 1987. Tissular expression of ABH and Lewis antigens in humans and animals: expected value of different animal models in the study of ABO-incompatible organ transplants. *Transplant. Proceed.*, 19(6): 4416-4420.
- Sarafian V, Taskov H, Popov A. 1994. Biological functions of carbohydrate ABH blood group determinants, *Biomedical Reviews*, 3: 55-63.
- Sarafian V, Tomova E. 2004. Phylogenetic study on the expression of human histo-blood group antigens A and B in vertebrate liver. *Trakia J. Sciences*, 2(1): 1-6.
- Sarafian V, Tomova E, Kalaydjiev S. 2004. Stomach expression of human histo-blood group antigens A and B in some vertebrates, *Acta Zoologica (Stockholm)*, 85(3): 191-199.
- Takiyama Y, Egami H, Pour PM. 1990. Blood group antigen expression in developing pancreas and in induced pancreatic cancer cells in Syrian hamsters. *Carcinogenesis*, 11(4): 577-582.
- Tomova E, Popov A, Sarafian V. 2001. Expression of human blood group antigens A and B in kidney and lung of some vertebrates. *Folia Biol. (Krakow)*, 49(3-4): 251-257.
- Yamamoto F. 1995. Molecular genetics of the ABO histo-blood group systems. *Vox Sang.*, 69(1): 1-7.